CHAPTER
20 Paediatric urology

Learning objectives

At the end of this chapter, you will be able to:

- Explain the indications for circumcision in childhood and list the complications
- Describe three levels of urinary tract obstruction and outline their management
- Describe the anomalies of hypospadias and epispadias
- List risk factors for urolithiasis and describe three methods of stone management
- Categorise with examples three differences of sex development (DSD)
- Describe the ileocystoplasty with appendicovesicostomy for managing neuropathic bladders

INTRODUCTION

Paediatric urologists are paediatric surgeons who subspecialise in the conditions outlined in this chapter; they also manage the acute and elective inguinoscrotal pathology described in *Chapter 17*. Surgeons in many specialities are consulted about the foreskin; this is covered in detail here. Specialist paediatric urological conditions include hypospadias, epispadias, bladder exstrophy, vesicoureteral reflux, renal duplications, urolithiasis and urinary tract obstruction. Obstruction occurs at three levels: dysfunction at the ureteropelvic junction, dysfunction at the ureterovesical junction and in the posterior urethra with congenital valves. Obstructions may present with fetal hydronephrosis. Postnatally, obstruction with infection causes renal damage. The relevant embryology and epidemiology are summarised. Choosing the right time to operate, often based on diagnostic imaging, and gentle tissue handling are central to achieving good outcomes with few complications. Diagnostic imaging includes ultrasonography, voiding cystourethrography and the use of the radioisotope technetium-99m (^{99m}Tc) linked to dimercaptosuccinic acid (DMSA) or mercaptoacetyltriglycine (MAG-3). The management of the neuropathic bladder may involve an ileocystoplasty with a continent catheterisable channel. Many specialist paediatric urological conditions require close follow-up and later transfer to specialist adult surgical care.

EMBRYOLOGY

Four areas of developmental biology are relevant: (i) the two stages of testicular descent; (ii) the Weigert–Meyer rule – in a duplex system the ectopic upper pole ureter has an orifice lying inferomedial to the lower pole ureter; (iii) the role of the urethral plate in the tubularisation of the urethra and the aetiology of hypospadias and its relevance to operative repairs; and (iv) morphological differentiation in relation to disorders, or differences, of sex development. These areas are addressed in the recommended further reading.

THE PENIS

Foreskin disorders and circumcision

Surgical referrals for foreskin problems are common in early childhood, and reassurance is often all that is needed after taking a careful history and examination. The foreskin, or prepuce, is a highly innervated, double-layered fold of skin. The inner layer is a mucous membrane and the outer layer is skin, with a mucocutaneous zone where the layers meet. The prepuce has similarities to the eyelids, labia minora, anus and lips. The prepuce provides mucosa and skin to cover the erect penis. The foreskin is adherent to the glans at birth and gradually separates in most boys by the age of 5 years and in the remaining before puberty, allowing the foreskin to become fully retractile. Forceful retraction is not recommended as it can cause tears and scarring. The adhesions are natural and not pathological. The foreskin may balloon on micturition as the plane between glans and prepuce develops. Ballooning is not an indication for circumcision. If spraying of urine on micturition is causing concern, the parent and child can be taught to partially draw back the foreskin so the meatus is unobstructed and spraying is reduced. Occasionally a nodule of entrapped smegma, termed a 'smegma pearl', accumulates in the developing plane between the glans and prepuce, causing parental anxiety. These are harmless collections that discharge on their own when the developing plane finally opens onto the exposed glans.

Carl Weigert, 1845–1904, German pathologist and anatomist known for work on cellular staining.
Robert Meyer, 1864–1947, German pathologist in Berlin, removed from his position for being Jewish, emigrated in 1939 to Minneapolis, MN, USA.

Circumcision, being the removal of the foreskin, is the oldest and most common surgical procedure and is usually performed for cultural reasons. About 40% of males worldwide are circumcised. Circumcision is performed in Judaism, on day 8 of life (brit milah), and in Islam (khitan), at varying ages. In early infancy, circumcision can be performed under local anaesthesia using simple devices like the PlastiBell or Gomco clamp. In older boys under general anaesthesia, the foreskin is removed with a blade or scissors, followed by attention to haemostasis and skin apposition with sutures or glue. Complications include bleeding, dehiscence, infection, cicatrix, adhesion formation, meatal stenosis, the removal of too little or too much tissue, cosmetic concerns and rarely urethral injury or amputation. Medical indications for circumcision include:

- **True phimosis**: the foreskin is non-retractile because of a tight fibrotic preputial ring.
- **Balanitis xerotica obliterans (BXO)**: a chronic, possibly autoimmune, preputial inflammation that may also affect the distal urethra and is rarely seen before 5 years of age. Boys present with progressive phimosis and white, hard preputial skin (***Figure 20.1***), dysuria and ballooning on micturition. Usually, circumcision is required, although some boys respond to topical corticosteroids. Follow-up is required to exclude meatal stenosis.
- **Recurrent balanoposthitis**: an inflammation of the glans penis and its retractile foreskin due to infection, irritation or trauma. Boys may present with pain, itching, rash, dysuria and a non-urethral penile discharge. Most boys have only one or two episodes and need no intervention, but a few have sufficient trouble with recurrence that circumcision is indicated.
- **Recurrent urinary tract infections (UTIs)**: though rare in most boys, UTIs are a particular risk with some anomalies, such as posterior urethral valves, where infection can lead to pyelonephritis, renal scarring and renal insufficiency. In these boys, circumcision may reduce those risks.
- **Paraphimosis**: sometimes, the prepuce retracts back over the glans and cannot be brought forward again; the glans swells and becomes painful. If manipulation fails, an emergency dorsal slit or circumcision is indicated.

Figure 20.1 Balanitis xerotica obliterans.

Hypospadias

The genital tubercle becomes a penis under the influence of androgens with a tubular urethra arising from the urethral plate. The urethral plate develops a diamond-shaped groove whose edges fold over and fuse in the midline, forming a tube. In girls, the urethral plate's homologue forms the vestibular groove with edges that do not fuse but form the labia minora. Hypospadias is a congenital malformation seen in 1 in 300 boys. The urethral opening lies on the ventral aspect of the penis anywhere from the proximal glans to the perineum in association with a ventral curvature (called a chordee) and a ventrally deficient foreskin leading to a dorsal 'hooded' prepuce. Clinicians should document phallus length, meatal location, glans volume, depth and width of the urethral plate, degree of chordee, foreskin appearance and the testes' presence and location. Circumcision is contraindicated because the foreskin may be needed for the reconstruction. The anomaly should be diagnosed in the newborn examination.

Hypospadias repair aims to achieve the usual meatal location and a straight penis to facilitate micturition and ejaculation. Distal hypospadias, where the opening is on the glans, may be repaired in a single stage, whereas more proximal openings and those with severe curvatures require staged procedures. Many operations have been described. One technique is the tubularised incised plate procedure, which widens and then tubularises the urethral plate (***Figure 20.2***). Staged repairs may use the foreskin as a first-stage graft, followed by tubularisation in a second stage. Complications include urethrocutaneous fistulae, meatal stenosis, glans dehiscence and hypospadias persistence.

Epispadias/bladder exstrophy

Epispadias is a rare dorsal penile defect with an opening whose upper limit lies anywhere from the penopubic junction to the glans (***Figure 20.3***). Epispadias may be part of the bladder exstrophy–epispadias complex in which the bladder and bladder neck are also open on the lower abdominal wall. Ileocaecal exstrophy (cloacal exstrophy) represents the most severe variant, in which there is a small exomphalos with an everted caecum and ileum separating halves of the bladder and, in males, a split penis. If we imagine hypospadias as the anatomy that might result from making an opening with scissors placed with one blade into the urethra and one blade ventrally, then epispadias is akin to making this opening on the dorsal aspect and through the pubis into the bladder for the bladder exstrophy. Children with epispadias have problems with urinary incontinence but are often otherwise healthy. Boys with epispadias and a functioning bladder neck may have a

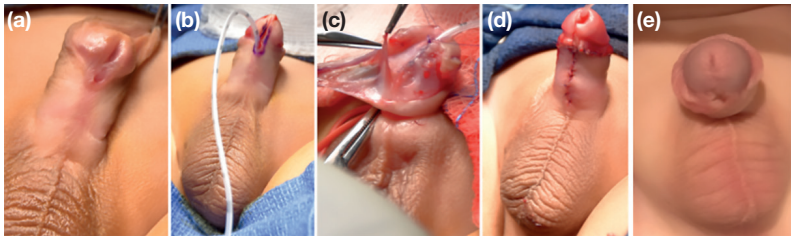

Figure 20.2 **(a)** Subcoronal hypospadias with dorsal hooded prepuce. **(b)** 5-Fr feeding tube in hypospadiac meatus. **(c)** Urethroplasty. **(d)** Creation of a terminal neo-meatus with skin closure. **(e)** Healed penis after hypospadias repair.

penile reconstruction around 2 years of age. Follow-up is required to monitor bladder emptying, continence and the upper urinary tracts, which may deteriorate if reconstruction causes a degree of obstruction.

UROLITHIASIS

The prevalence of urolithiasis in children varies from around 1–5% in Asia, 5–10% in Europe to 15% in North America. Investigations include serum electrolytes, urinalysis, urine culture and stone analysis. Common metabolic risk factors include high oxalate and calcium levels and low levels of citrate in the urine. Therapy aims to alter these levels to reduce recurrence. Approximately 25% of stones are caused by a UTI from urease-producing bacteria, *Proteus mirabilis* or *Klebsiella pneumoniae*. Anatomic anomalies leading to urinary stasis and urolithiasis include ureteropelvic junction obstruction, polycystic kidney and neurogenic bladder. Children may present with flank or abdominal pain, gross haematuria, dysuria, nausea or vomiting. Stones are easily detected with ultrasound. Non-contrast computed tomography scans are very sensitive but involve ionising radiation.

Small stones may pass with generous oral hydration and analgesia. Some stones with associated infection require intravenous hydration and antibiotics. α-Blockers and calcium channel blockers may reduce dysmotile ureteric contractions initiated by a stone while preserving helpful expulsive peristaltic activity. Reimaging may confirm the passage of a stone. Intervention may be required to manage pain, obstruction and treatment-resistant stones. Extracorporeal shock wave lithotripsy (ESWL) can safely and effectively fragment stones smaller than 2 cm using focused, high-energy shock waves delivered under general anaesthesia. Ureteroscopy allows fragmentation and removal of stones smaller than 2 cm from the ureter or kidney but is avoided in those younger than 5 years. Percutaneous nephrolithotomy (PCNL) can be used to extract stones from the kidney through a dilated tract. PCNL is used for stones larger than 2 cm, ESWL-refractory stones smaller than 2 cm and multiple stones.

Summary box 20.1

Urolithiasis

- Children with urolithiasis should be evaluated for metabolic risk factors
- Urological management depends on the size of calculi, age, number of stones and the presence of obstruction, infection or pain

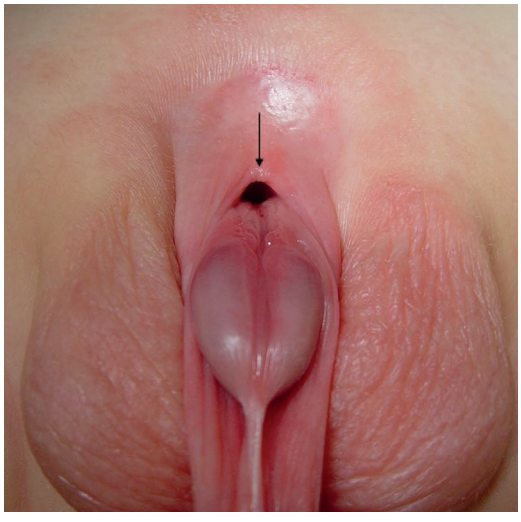

Figure 20.3 Penopubic meatus (arrow) in epispadias in a boy.

URINARY TRACT OBSTRUCTION

Antenatal fetal hydronephrosis

Hydronephrosis – a dilated renal pelvis – is found in 1% of antenatal scans and most commonly it resolves, especially if the dilatation is mild to moderate. Severe dilatation is associated with urinary tract obstruction or vesicoureteral reflux. Antenatal interventions are rarely indicated except in posterior urethral valves (PUVs), but postnatal imaging is needed to confirm resolution or make a diagnosis. Amniotic fluid is principally fetal urine; thus, if there is antenatal bilateral hydronephrosis with decreased amniotic fluid, PUV is a likely cause. If the PUV obstruction is thought to be damaging the kidneys, then there may be a role for an antenatal vesicoamniotic shunt to take the pressure off the upper tracts.

Radioisotope renal imaging

The metastable radioisotope ^{99m}Tc emits gamma rays during an isomeric transition to ^{99}Tc. It has a 6-hour emission half-life and a 1-day biological half-life, so imaging with low exposure is possible. For static imaging, ^{99m}Tc is linked to DMSA and given intravenously; an image is captured after 2–3 hours to assess renal morphology (e.g. agenesis and duplex systems), structure (e.g. renal scarring in reflux nephropathy) and function. For dynamic imaging, ^{99m}Tc is linked to diethylenetriaminepentaacetate (DTPA) or MAG-3 and given intravenously; a series

of images capture renal excretion. If the renal blood supply is compromised, the kidney is not imaged; if it is well perfused but partially obstructed, delayed transit is seen. Activity curves and comparison with the contralateral kidney are informative. MAG-3 is preferred to DTPA in neonates and children with impaired function and when an obstruction is suspected since it is more efficiently extracted from the blood by the proximal tubules and clearance correlates with blood flow. After extraction by the proximal tubules, MAG-3 is secreted into the tubular lumen, whereas DTPA is filtered by the glomerulus and provides a measure of the glomerular filtration rate.

Ureteropelvic junction obstruction

Ureteropelvic junction (UPJ) obstruction, also often called pelviureteric junction (PUJ) obstruction, describes an incomplete and intermittent reduction in urine flow from the kidney to the proximal ureter and occurs in 1 in 1000 live births with a male and left-sided predominance. It is the most common cause of serious antenatal hydronephrosis. Commonly a disruption of circular muscle or collagen fibres in the proximal ureter results in an intrinsic narrowing near the renal pelvis. Extrinsic compression is less common and results from an aberrant renal vessel compressing the ureteropelvic junction. Most cases are diagnosed in the postnatal evaluation of an antenatally detected hydronephrosis, although some newborns present with an abdominal or flank mass and a history of urinary tract infection or haematuria. Older children may present with severe intermittent flank or abdominal pain associated with nausea and vomiting, known as Dietl's crisis. MAG-3 imaging confirms the diagnosis, and knowing the differential renal function helps to decide between surgical and non-surgical management (***Figures 20.4 and 20.5***).

In symptomatic children, a pyeloplasty is indicated. In many countries, this is now commonly performed laparoscopically, with some using robotic assistance. A pyeloplasty involves transection at the obstruction and the fashioning of a funnel-like anastomosis; a temporary stent and a drain may be placed. Follow-up with serial ultrasounds and MAG-3 imaging is required.

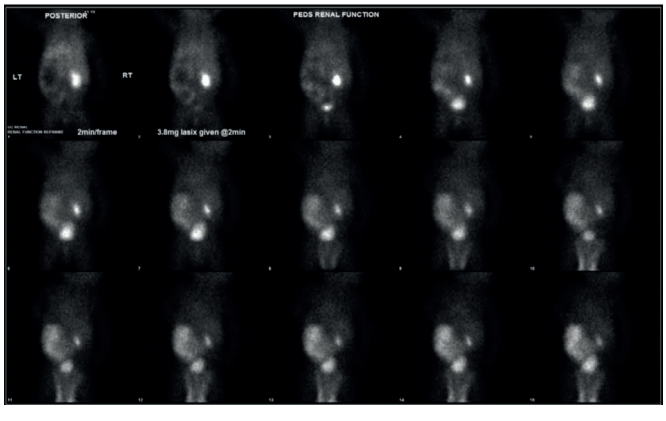

Figure 20.4 Mercaptoacetyltriglycine (MAG-3) renal scan showing poor drainage of a hydronephrotic left kidney due to partial ureteropelvic junction obstruction. Note that nuclear scans are shown as if looking from behind the patient.

Ureterovesical junction obstruction/ megaureters

Ureterovesical junction (UVJ) obstruction is the second most common cause of antenatal hydronephrosis and arises from an adynamic and stenotic region obstructing the distal ureter near the bladder (***Figure 20.6***). Older children may have a distal ureteric polyp or calculus and present with a UTI, haematuria, abdominal pain or a hydronephrotic mass. Ultrasonography shows ureteric dilation (megaureter), hydronephrosis or both (hydroureteronephrosis). Importantly, obstruction is not the only cause of a dilated ureter. A primary megaureter refers to one that arises from an abnormality at the junction, whereas a secondary megaureter arises from a problem in the bladder or urethra (myelomeningocele/neurogenic bladder, PUV). Although reflux may cause a megaureter, it is also possible to have a refluxing obstructed megaureter, and so a voiding cystourethrogram is needed to look for reflux. A MAG-3 renal scan indicates the severity of obstruction. If intervention is required, ureteric reimplantation is performed.

Vesicoureteral reflux

Vesicoureteral reflux (VUR) is the retrograde flow of urine from the bladder to the upper urinary tracts. Primary VUR occurs because of a congenitally short intravesical ureter, resulting in inadequate closure of the UVJ during bladder contractions, and is seen in 1% of newborns. Secondary VUR follows from elevated intravesical pressure and is typically caused by PUV or

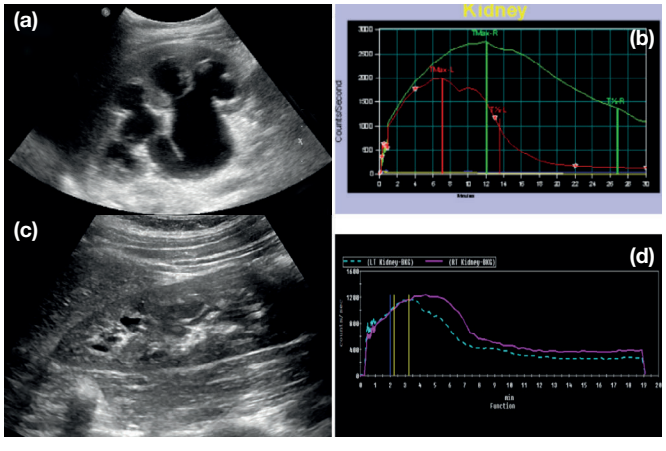

Figure 20.5 (a) Preoperative ultrasound of a right kidney with ureteropelvic junction obstruction showing hydronephrosis. **(b)** Preoperative mercaptoacetyltriglycine (MAG-3) activity curve showing delayed excretion of the obstructed right kidney with a half-life of 26 minutes. **(c)** Ultrasound image of the right kidney after a pyeloplasty showing resolution of the hydronephrosis. **(d)** Postoperative MAG-3 activity curve graph showing improved excretion with a half-life of 7.6 minutes.

Józef Dietl, 1804–1878, Austrian–Polish physician and Mayor of Kraków, reformed medicine by showing through experiments that bloodletting was not only useless but dangerous.

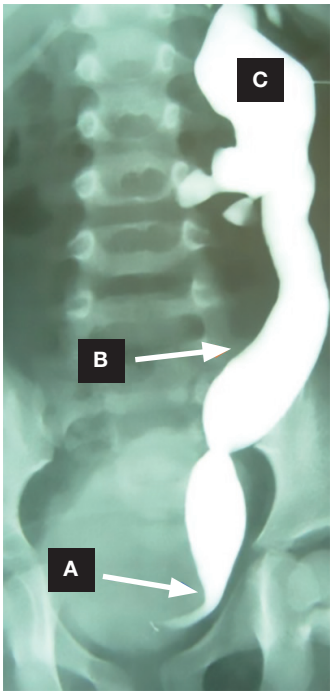

Figure 20.6 A retrograde pyelogram showing a left-sided ureterovesical junction obstruction (A), causing a megaureter (B) and hydronephrosis (C).

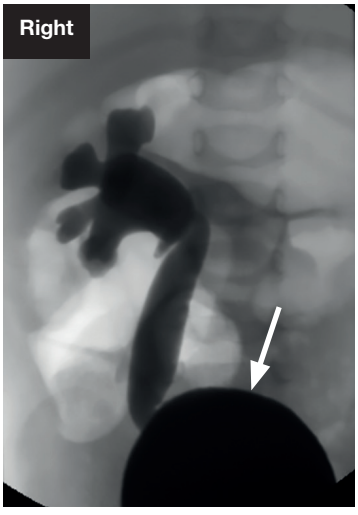

Figure 20.7 Voiding cystourethrogram demonstrating right-sided vesicoureteral reflux. The bladder is full of contrast (arrow).

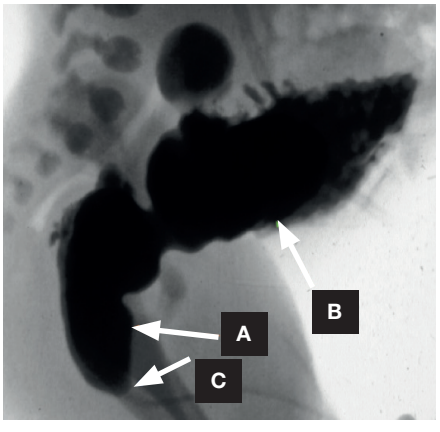

Figure 20.8 Lateral view showing a dilated posterior urethra (A) and trabeculated bladder (B) due to posterior urethral valves (C), seen on a voiding cystourethrogram.

a neurogenic bladder. VUR may be seen with hydronephrosis on an antenatal ultrasound or with a symptomatic UTI postnatally. A voiding cystourethrogram establishes the diagnosis and severity of VUR (*Figure 20.7*). Mild VUR typically resolves spontaneously as the patient grows and the intravesical ureter matures and lengthens. These children are managed with surveillance if toilet-trained or prophylactic antibiotics if they are not. Moderate-to-severe VUR less commonly resolves and recurrent UTIs may lead to pyelonephritis and renal parenchymal loss from scarring. Persistent or severe VUR can be managed with a subureteric Teflon injection (STING), which alters the anatomy at the UVJ and limits reflux, or with ureteric reimplantation. Long-term follow-up is required.

Posterior urethral valves

PUVs are membranous folds that obstruct the lumen of the posterior urethra, affecting about 1 in 4000 live-born boys. Girls are not affected. About one-third are identified antenatally with bilateral hydronephrosis, a dilated bladder and a dilated posterior urethra, which, on imaging, looks like a keyhole. In severe cases, there is oligohydramnios and lung hypoplasia. Postnatal presentations include urinary tract infections, bladder distension and voiding dysfunction. The diagnosis is confirmed on a voiding cystourethrogram, which shows a dilated posterior urethra with a thick-walled bladder (*Figure 20.8*). Ultrasonography looks for hydronephrosis and a thickened bladder. Renal function can be assessed with routine blood tests and glomerular filtration rate or a DMSA scan. The valves are ablated or resected; close follow-up is needed since bladder dysfunction is common and 30% develop renal failure.

Summary box 20.2

Urinary tract obstruction

- Prenatal fetal hydronephrosis often resolves under observation alone
- Severe ureteropelvic junction obstruction warrants a pyeloplasty
- Ureterovesical junction obstruction is one cause of megaureter
- Vesicoureteral reflux: severity is determined by voiding cystourethrography
- Posterior urethral valves lead to renal failure in 30% of affected boys

DUPLEX SYSTEMS

One in a hundred people have an upper renal moiety draining into a duplicated ureter. Both ipsilateral ureters may fuse such that only one ureter enters the bladder, or the duplicated ureter may have an ectopic opening into the bladder, urethra, vagina, vulval vestibule, seminal vesicle or rectum and is a rare cause of wetting. A vesical ectopic ureter may be associated with a dilated and obstructed intravesical length of ureter. Such a structure is known as a ureterocele and may be detected antenatally. The ectopic upper pole ureter typically has an orifice lying inferomedial to the lower pole ureter; an arrangement known as the Weigert–Meyer rule. The upper renal moiety has a ureter that may be obstructed at the bladder, whereas the lower renal moiety has a ureter with a predisposition to reflux.

DISORDERS OR DIFFERENCES IN SEX DIFFERENTIATION

Some, but not all, children with abnormalities of their sex chromosomes, gonads or reproductive anatomy are considered to have a disorder or difference in sex differentiation (DSD). Isolated undescended testes, hypospadias and labial adhesions are excluded. Unfortunately, there is no consensus on the indications, timing, best procedures or how to evaluate DSD surgery. The classification of disorders into groups is complex and controversial. For simplicity, only the following groups are described here: 46-XX DSD, 46-XY DSD and sex-chromosome mosaicism DSD variants. DSD management benefits when the paediatric urologist works in a multidisciplinary team, including a geneticist, endocrinologist, an adolescent gynaecologist and a psychologist.

The **46-XX DSD** group is exemplified by congenital adrenal hyperplasia (CAH), in which gender is usually straightforward (female), except with late diagnoses and severe masculinisation. At birth, the urethra may open on a prominent genital tubercle, appearing like a small phallus and looking similar to a 46-XY boy with severe hypospadias and non-palpable testes. In 46-XX CAH, the vagina opens into the posterior wall of the urethra a variable distance from the bladder neck but not higher than where the verumontanum, a Müllerian structure, is typically located in the male urethra. Genital fold fusion varies from a vulval-like to a scrotal-like appearance.

The **46-XY DSD** group is exemplified by androgen insensitivity syndrome (AIS), 17β hydroxysteroid dehydrogenase (17β HSD) deficiency and 5α reductase deficiency. AIS is complete (CAIS), with a feminine phenotype, or partial (PAIS), in which the external genitals are undermasculinised at birth and undervirilised at puberty. Infants with CAIS (reared as girls) may present with bilateral inguinal hernias or with inguinal testes thought to be prolapsed ovaries. Similarly, those with 17β HSD deficiency and 5α reductase deficiency, having low androgens, may have an external feminine phenotype with palpable inguinal testes undergoing virilisation at puberty. In challenging cases, controversy surrounds gender assignment, sex of rearing and surgery.

One critical issue is the fate of the testicles: should gonads be left alone until the individual can determine their gender for themselves? Or, if female sex rearing is decided on, should they be removed early to avoid virilisation at puberty? If conservative management is chosen, temporarily blocking virilisation with a gonadotropin-releasing hormone analogue is an option until gender identity is determined.

Sex-chromosome mosaicism is exemplified by 45X/46XY DSD. These individuals may have a hemiscrotum containing a testis-like gonad, paired with a labia majora with an inguinal or impalpable streak gonad; a streak gonad has stromal tissue without tubules or follicles. There is usually severe hypospadias.

NEUROPATHIC BLADDER

A myelomeningocele, lipomyelomeningocele, fatty filum or an occult tethered cord can cause a neuropathic bladder that may need lifelong care to protect the kidneys from high urinary pressures and reflux, and support continence and independence where appropriate. If reconstructive surgery is needed, it must follow detailed assessments of (i) the adequacy of the bladder neck/sphincter complex, (ii) bladder capacity, (iii) the need for a cutaneous catheterisable channel, and (iv) any associated faecal continence procedures. Bladder neck procedures include endoscopic injections, slings, reconstructions and bladder neck closure. Bladder capacity and compliance can be increased with a bladder augmentation (e.g. ileocystoplasty), which takes the pressure off the upper tracts. An appendicovesicostomy (Mitrofanoff), using the appendix as a conduit between the skin and the bladder, allows intermittent catheterisation as an alternative to urethral catheterisation (*Figure 20.9*).

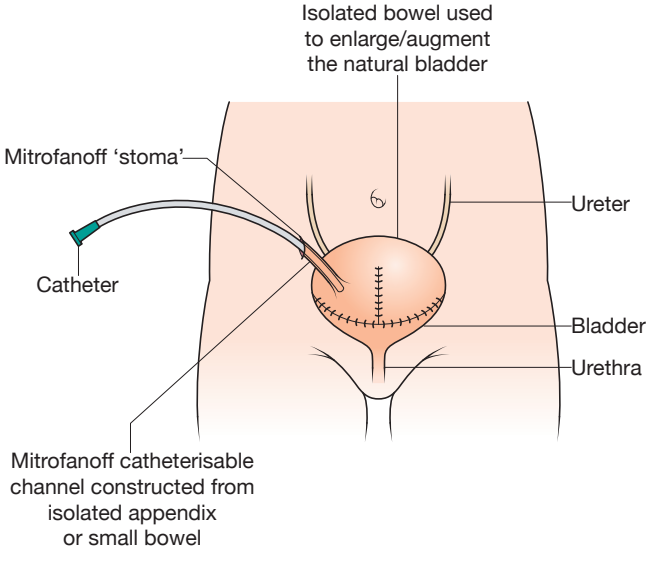

Figure 20.9 Mitrofanoff appendicovesicostomy draining an ileocystoplasty, which augments and converts a high-pressure bladder into a low-pressure system to protect the kidneys in a patient with a neuropathic bladder.

Johannes Peter Müller, 1801–1858, German physiologist and comparative anatomist after whom the paramesonephric duct structures are named.
Paul Mitrofanoff, b. 1934, paediatric surgeon, Rouen, France, devised the appendicovesicostomy in the mid-1970s.

TESTICULAR TUMOURS

Testicular tumours are rare. Most prepubertal tumours arise before 3 years and are benign, allowing testis-sparing surgery. Malignant tumours in older boys require an orchidectomy (performed through the groin) and selective chemotherapy. Germ cell tumours include the teratomas and epidermoid cysts (typically benign) and the malignant yolk sac tumours, seminomas, choriocarcinomas and embryonal carcinomas. Gonadal stromal tumours are typically benign and include Leydig cell tumours, Sertoli cell tumours, juvenile granulosa cell tumours and gonadoblastomas.

FURTHER READING

Grinspon RP, Rey RA. Disorders of sex development. In: Kovacs C, Deal C (eds). *Maternal–fetal and neonatal endocrinology*. San Diego, CA: Academic Press, 2020: 841–67.

Gundeti MS. *Surgical techniques in pediatric and adolescent urology*. Delhi: Jaypee Brothers Medical Publishers, 2019.

Hutson JM, Thorup JM, Beasley SW. *Descent of the testis*. Cham: Springer, 2016.

Franz von Leydig, 1821–1908, German zoologist and comparative anatomist, discovered the Leydig cells.
Enrico Sertoli, 1842–1910, Italian physiologist, discovered the Sertoli cells of the testis.